

# Citywide Conference 5/29

Thomas Jefferson fellows

# Case 1

- 60's year old male, no known medical history
- Sleeps at a SEPTA station, forced out and presented to ED
- Presented to ED with fatigue
- On evaluation, very combative, not answering appropriately and covered in feces
- In ED, febrile to 101.9F, with otherwise normal vital signs
- Unable to obtain ROS as patient was very combative and delirious

# History

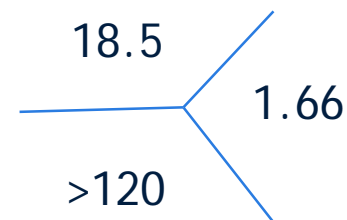
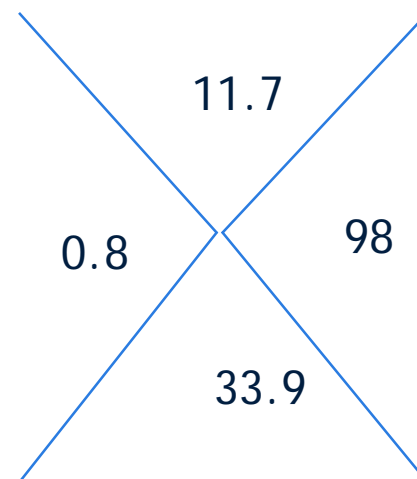

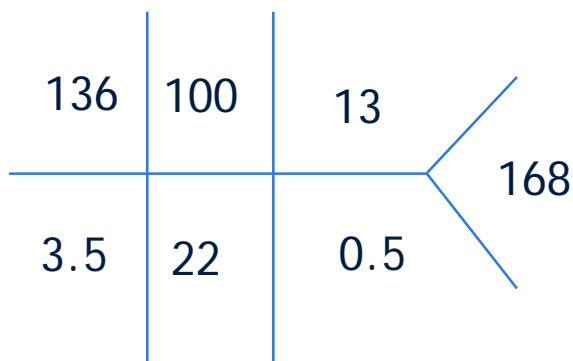
- PMH: none
- PSH: none
- Social history: No family around per patient, minimal alcohol use, no drug use, no sick contacts, not sexually active. States he traveled around the world but unable to note where. May have been in the military. Lives in a house and intermittently in a shelter. Does endorse bug bites, but cannot expand further. No contact with animals.
- Medications: none
- Allergies: NKDA

# Physical exam

- Physical Exam
  - VS: T 101.9F, HR 98, Sats 99% on RA, BP 118/70
  - General: Thin, cachectic
  - HEENT: no scleral icterus, no thrush, poor dentition
  - CV: RRR no m/g/r
  - Lungs: CTAB
  - Abdomen: soft, non tender, non distended, normoactive bowel sounds
  - Ext: no edema
  - Genitalia : unable to examine
  - Skin: no rashes, lacerations
  - Neuro: moving all extremities, unable to assess orientation
  - Psych: combative, inappropriate answering

# Labs

- Labs
  - HIV negative
  - Stool infectious panel negative
  - C diff negative
  - Ferritin 32,642
  - Lactate 2.4



# Imaging

- CT A/P: Fluid filled mildly dilated colon most pronounced in rectosigmoid colon, consistent with history of diarrhea. Dilated and fluid filled esophagus suggesting GERD. Diffuse wall thickening with increased mucosal enhancement in the stomach suggesting gastritis.
- RUQ US: no sonographic abnormality in liver; patent hepatic vasculature with normal flow

# Bone marrow biopsy

- Bone marrow biopsy: polyclonal plasma cells and plasmacytoid cells are presents in blood and bone marrow. Macrophages in the bone marrow are increased and show mild phagocytic activity, consistent with hemophagocytic lymphohistiocytosis.

# Discussion

- 60's M no known past medical history, presents with a febrile illness, transaminitis, pancytopenia, and hemophagocytic lymphohistiocytosis



## Hospital course/labs

- Urethral swab HSV-1 PCR +
- Serum HSV-1 PCR  $1.6 \times 10^7$  copies
- Diagnosed with HLH secondary to HSV-1
- Negative labs: rickettsial panel, HHV6 serum PCR, Hep A/B/C serologies, blood cultures, EBV serum PCR

## Hospital course

- Patient's LFTs and lab abnormalities started to improve prior to the HSV serum PCR reporting
- Mental status improved
- He was started on IV acyclovir
- Transitioned to PO acyclovir to complete a 14 day course on discharge

# Herpes Simplex Virus hepatitis

- First described in 1969
- Cause <1% of all liver failure and <2% of viral causes of liver failure
- Risk for disseminated disease is described in organ transplant recipients, HIV, malnutrition, third trimester pregnancy after oro-genital infection
- Can progress to fulminant liver failure and death
- >80% mortality when untreated

# HSV hepatitis

- Can occur in both primary infection and reactivation
- Typical oral/genital lesions are seen in about 30% of patients
- Symptoms: LFTs>500, fever, coagulopathy, encephalopathy, leukopenia, thrombocytopenia, acute renal failure
- 90% of patients will have characteristic “anicteric hepatitis”
  - Significantly high transaminases with relatively low or normal Br
  - AST > ALT
- Gold standard for diagnosis is liver biopsy
  - Cowdry type A inclusions, nuclei with large eosinophilic ground glass like inclusions surrounded by clear halo
  - Viral PCR testing is useful

# HSV-1-Hemophagocytic lymphochistiocytosis

- HLH is disorder of mononuclear phagocytic system - proliferation of non-neoplastic histiocytes (primary or secondary)
- Often secondary to herpes viruses, most often EBV/CMV
- HLH associated with diagnosed viral infections carries a worse prognosis
- Described in case reports in immunocompetent patients
  - Patient with HSV1 pneumonia and ARDS
  - Patient with MOF with EBV and HSV1 co-infection
  - Patient with primary disseminated HSV1

# Chief Complaint

40's yo woman presented with  
syncope

# Case

1/2018: Cooking at home, became dizzy and syncopal, hit her head and R elbow on hot stove, with resultant burn injury to the elbow. Went to OSH for evaluation, transferred to TJUH.

ROS: + Occasional palpitations, fatigue, decreased appetite, 10-lb unintentional weight loss past 4-5 months. No chest pain, SOB, fevers, chills, URI symptoms, dysphagia/odynophagia, abdominal pain, diarrhea or urinary complaints.

# History

**Home Medications:** none

**Allergies:** NKDA

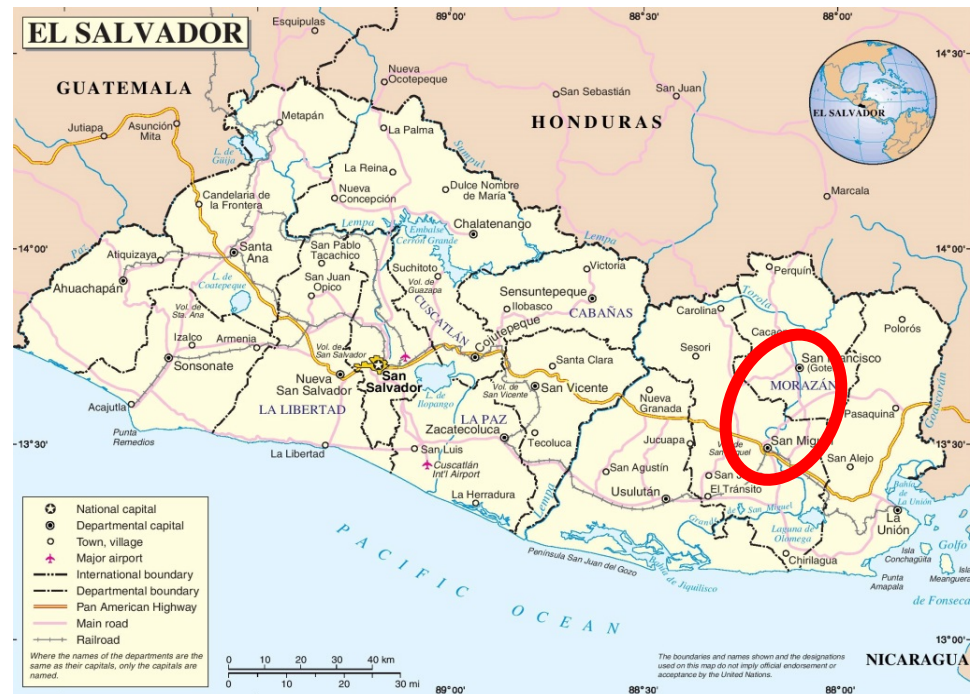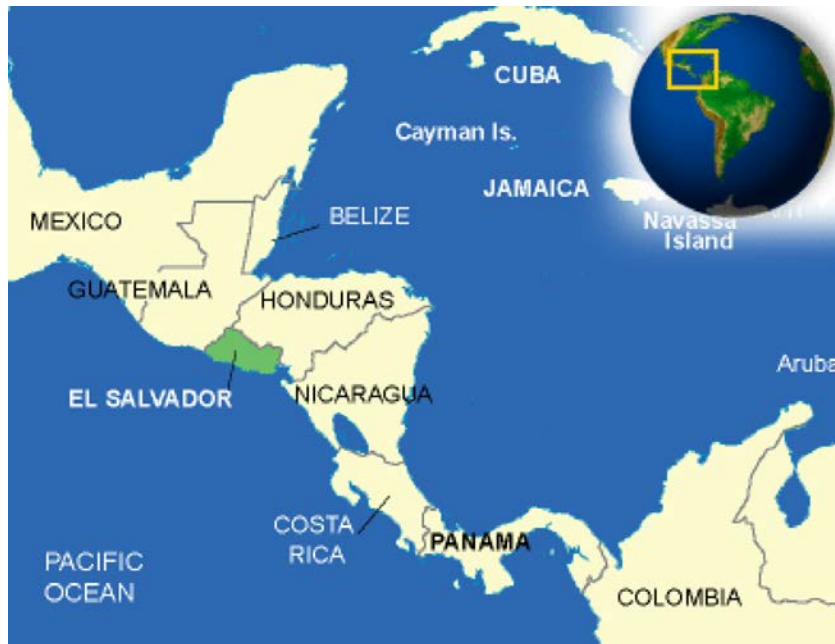**PHx:** Hashimoto's thyroiditis (dx OSH, 03/2016), ? stroke (2016)

**PSHx:** two C-sections (uncomplicated)

**FHx:** No family members with known CAD, HLD or risk factors for MI

**Social Hx:** Born in **El Salvador**, lived in Cacaopera (a small village) in Morazan, emigrated to US (Bucks County) in 2005 with her previous partner and children. She is separated from her partner several years ago due to an abusive relationship, currently lives with her 3 children (ages 10, 20 and 25). No pets. She works for a company that prepares seafood. Never smoker, no alcohol/recreational drug use. No recent travels, has not been back to El Salvador since emigrated.





# Physical Exam

## Vital Signs:

T 96.8, BP 110/70, P 120s, BMI 22

General: conversant, in NAD

HEENT: sclerae anicteric, no oral lesions, neck supple, trachea midline

CV: **irregularly irregular, tachycardic**

Pulm: CTAB, no wheezing

Abd: soft, nontender, not distended, +BS

Lymphatics: no palpable lymphadenopathies

Extremities: no edema, 2+ pulses

Skin: **R elbow burn wound and R thigh graft site clean**

Neuro: A&Ox3, no focal deficits, ambulatory normal gait

# Labs/Studies

CBC (normal diff), CMP wnl

TSH <0.02, total T3 of 361, free T4 of 5.5, anti-TPO Ab >1000, TSI >700

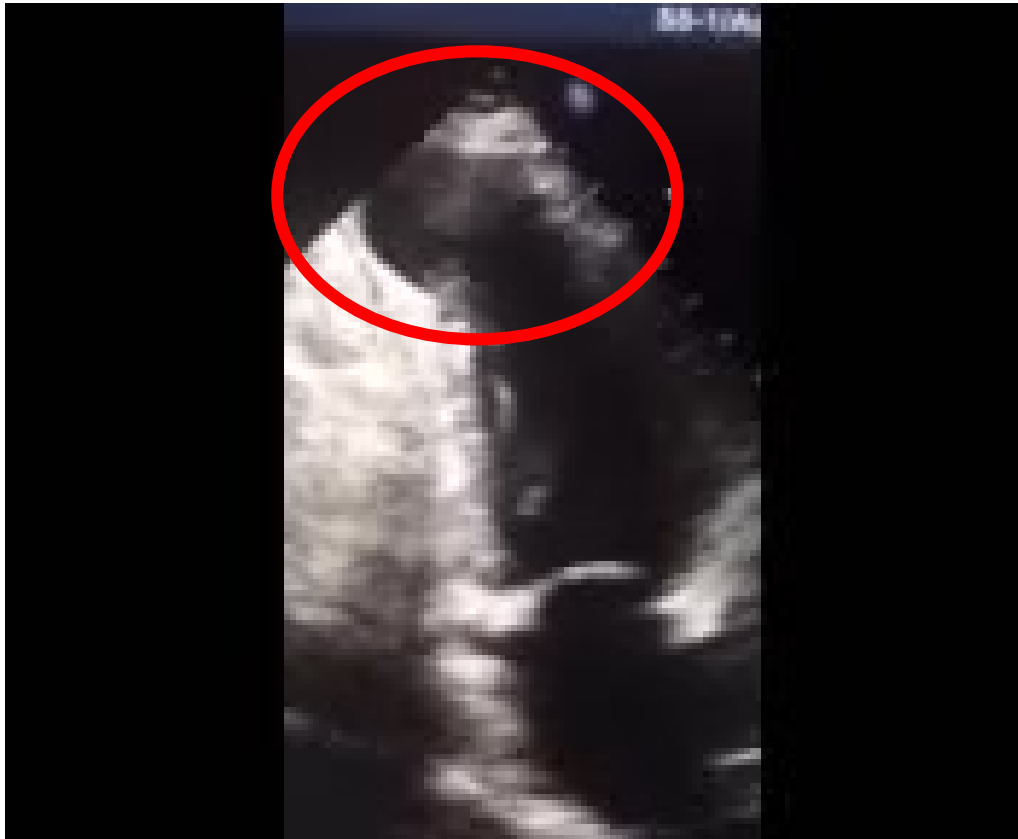NM Thyroid scan, 1/2018:

Slightly enlarged thyroid with increased activity c/w Graves' disease. There is patchy uptake within the gland with focal areas of increased and decreased activity c/w multinodular goiter.

# Case

- Underwent burn surgery/R thigh graft, uncomplicated, wounds healing
- Developed afib with RVR, found to have abnormal thyroid studies and NM thyroid scans -> diagnosed with Graves' disease -> started methimazole
- Afib eventually controlled, converted to sinus rhythm with beta-blocker
- During Cardiology evaluation, a **very large LV aneurysm** was seen on TTE, no significant systolic dysfunction noted

# Transthoracic Echocardiogram



- Low normal LV systolic function (EF 55%) with segmental WMA.
- **Focal apical inferior aneurysm** (thinned, 2.8cm diameter) with wide neck (less likely pseudoaneurysm) and peri-apical akinesis.
- Normal RV size and function.
- LA is moderately dilated. No pericardial effusion
- No stenosis or regurgitation.

# Discussion

1. What test would you order to make the diagnosis?
2. Would you treat this condition now? Why and why not?



# *Trypanosoma cruzi* IgG+

# Chagas Cardiomyopathy (CC)

- Chronic CC is the most frequent and severe manifestation of chronic Chagas disease, with **latent period of 5-30 years**
- Prevalence: 8.5% in asymptomatic individuals vs. **55% in individuals with moderate-severe cardiac impairment**
- Pathogenesis is not completely understood, with 4 major MOAS: neurogenic disturbances, microvascular derangements, **parasite-dependent damage, and immune-mediate tissue injury**
- Arrhythmia, heart failure, thromboembolism, stroke
- Typical ECG findings may include BBB, incomplete or fascicular heart block or ventricular arrhythmia
- Nonischemic



# Diagnosis

## Acute infection:

- Immunocompetent: Wet prep or Giemsa-stain, **serology in acute setting can be non-reactive**
- Immunocompromised: biopsies in bone marrow/LN/epimyocardium/skin/CSF/pericardial fluid

## Chronic infection:

- Serology: IgG -> **2 different Ag tests (ELISA, IFA or immunoblot)**
- No gold standard reference exists
- Blood donation screening is widespread in US since 2007

# Treatment

- “All cases of acute or reactivated Chagas disease and for chronic *Trypanosoma cruzi* infection in children up to age 18. Congenital infections are considered acute disease. Treatment is strongly recommended for adults up to 50 years old with chronic infection who do not already have advanced Chagas cardiomyopathy.”
- Acute infections can be cured
- 1st line: Benznidazole 5-7 mg/kg/day BID x  $\geq 60$  days (FDA approved for children 2-12, not yet for adults, available through CDC under IND protocol)
- Nifurtimox TID or QID x  $\geq 90$  days (free through WHO-Bayer agreement, not FDA approved, available through CDC under IND protocol)

# Hospital Course

- CT chest /abdomen/pelvis w/ contrast:
  - **Normal esophagus in caliber throughout**, with mild prominence of rectal ampulla. Remainder of the large bowel is normal in caliber. No esophageal or bowel dilatation.
  - Rim-enhancing lesion centrally located in the uterus, may be a fibroid.
- Plan to follow up to start treatment when medication is approved by CDC after confirmatory tests are done.

# Follow Up

- ID clinic visit, 2/28
  - Patient recalls having seen “chinche picuda” or “telapate” (aka kissing bug) in her house in El Salvador
  - She recalls of an episode of severe febrile illness at age 17; denies h/o periorbital edema
- CDC confirmed diagnosis via repeat serologies
  - Mailed us Benznidazole to initiate therapy
- Hospitalized 5/3-5/7 for palpitations, started warfarin
- ID clinic visit, 5/9 and 5/23
  - Started Benznidazole 5 mg/kg/day (BID dosing), increased to 6.5 mg/kg/day, 100% compliance, no side effects
  - Follow up in 2 weeks

# References

1. <https://www.cdc.gov/parasites/chagas/index.html>
2. <http://www.who.int/chagas/en/>
3. Acquatella H. Echocardiography in Chagas heart disease. *Circulation* (2007). 115 (9): 1124-1131.
4. Bern, C. Chagas' Disease. *NEJM* (2015). 373: 456-466.
5. Hagar JM. Chagas' Heart Disease in the United States. *NEJM* (1991). 325:
6. Kirchhoff LV. Trypanosoma spp (American Trypanosomiasis, Chagas' disease): biology of Trypanosomes. *Mandell* (2015); 2: 3108-3115.
7. Mohammed MT. An infrequent cause of apical ventricular aneurysm in the United States. *Heart Views* (2017, Apri-Jun). 18(2): 54-57.
8. Rassi A, JR and Neto JAM. Chronic Chagas cardiomyopathy: a review of the main pathogenic mechanisms and the efficacy of aetiological treatment following the Beznidazole Evaluation for Interrupting Trypanosomiasis (BENFIT) trial. *Mem Inst Oswaldo Cruz* (2017). 112(3): 224-235.

# Citywide

Mitch Sternlieb

5/29/18

## Case

- 60's M Renal transplant (CMV D-/R+) 9/2016. Had been on mycophenolate, tacrolimus and prednisone. Complicated by AKI and persistent BK viremia. Mycophenolate held and prednisone increased from 10 mg daily to 15 mg daily around 12/2017 as well as leflunomide.
- Over next 2 months developed progressive BLE weakness and difficulty standing from sitting. In mid march he reported this weakness to his outpatient nephrologist leading to direct admission.
- He was thus admitted for 4 days in mid March. His weakness was attributed to steroid-induced myopathy (normal CK). He had no fevers and his mental status documented to be AOx3. He received wound care for RLE abrasion. His steroid was stopped and he was discharged with home PT.
- He was readmitted 7 days later (end of march) with ongoing falls, weakness and fatigue. He now had a dry cough and fever in the ED 100.9-101.9 F. WBC 8.3. AKI, Crt 1.7 on prior admission, now 2.7. CXR with RML opacity.

- He was started on IV vancomycin and Piperacillin-tazobactam for CAP with recent healthcare exposure. Fevers persisted another 2 days but defervesced (but was on standing acetaminophen).
- Hospital day 3-4 changed to levofloxacin. Continued to have low temps 99.6 F
- Hospital days 4-10 changed to doxycycline for possible RLE cellulitis around prior abrasion. Continued to have fevers. Patient complained of headaches and had fluctuation in mental status (disorientation and lethargy). A biopsy of the RLE wound and a renal biopsy were performed.
- ID consulted on hospital day 9 because RLE cellulitis not getting better.



- Past medical history: Thrombocytopenia, anemia, immunosuppression, BK viremia, polycystic kidney disease, hypertension, hyperlipidemia
- Surgical history: Sinus surgery, renal transplant, nephrectomy.
- Family history: Heart disease and cancer.
- Social history: Former smoker. Lives with his wife and children in Philadelphia and former data center employee. Poor historian but no obvious recent epidemiology in terms of travel, pets, or environmental exposures.
- Allergies none.
- Medications: Relevant for doxycycline 100 mg b.i.d. and tacrolimus. No steroid.

T-max last 24 hours 99.4. Temperature 97.8° pulse 95, blood pressure 134/65, respiratory rate 18, 92% on room air. 135 lb.

General: Nontoxic no acute distress. Adequately nourished.

HEENT: Head is normocephalic. Sclerae are anicteric. No conjunctival lesions. Mucous membranes are moist and he has poor dentition.

Neck: Supple with no meningismus normal range of motion.

Heart: Regular rate and rhythm without murmur.

Lungs: Faint crackles on the right but otherwise clear to auscultation.

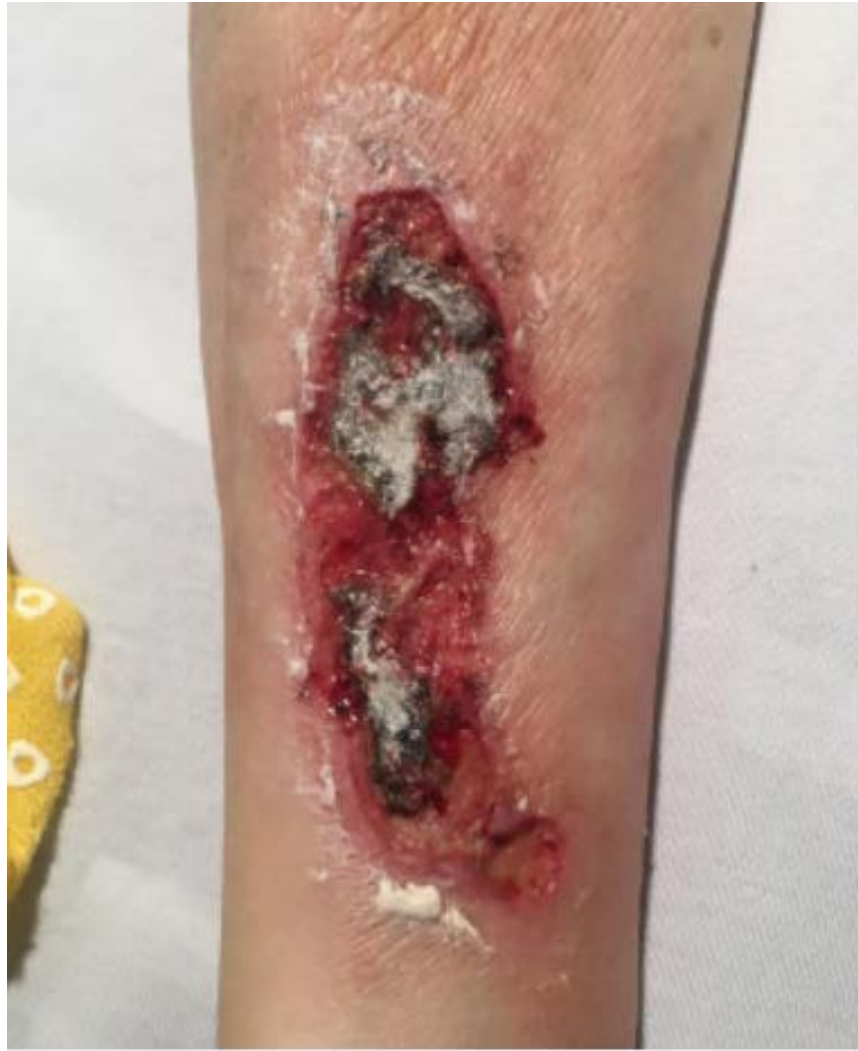Abdomen: Nontender nondistended. Transplant graft in the right lower extremity is nontender. Normal bowel sounds.

Genitourinary: No genital lesions. Normal male genitalia.

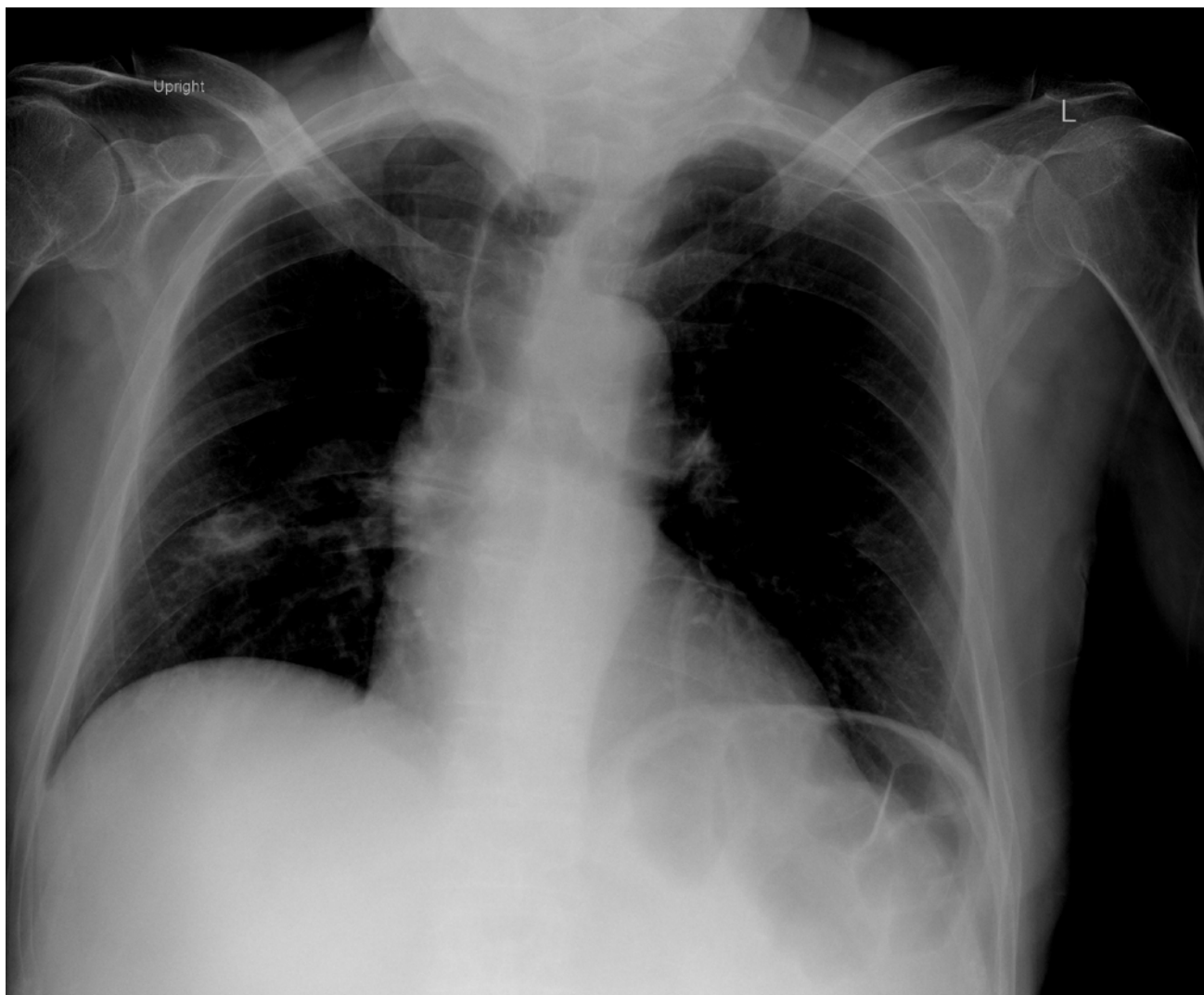
Musculoskeletal: Muscles are nontender. No evidence of septic arthritis.

Neurologic: Oriented to self only. Awake and interactive but poor memory and poor insight. Cranial nerve, Strength, muscle bulk and tone, sensory exam, and reflex exams were normal without asymmetry.

Skin: Scattered ecchymoses. Small splinter lesions on right hand in 3rd and 2nd digit fingernail. Large wound on RLE dressed. Had to review images as patient did not tolerate removal of dressings.



- WBC 5.2, hemoglobin 7.7, platelets 162. Normal differential
- Creatinine back down to 1.8, albumin 2.9, glucose 338, liver enzymes normal.
- Admission urinalysis with 3+ leukocyte esterase and 28 white blood cells. Urine culture no growth.
- RSV and flu negative. Blood cultures no growth x5d.
- BK virus plasma in mid March 18,000 copies. This admission it was 17,000.
- CMV PCR plasma <100
- CT brain non-contrast: patchy white matter changes, likely old ischemia.
- Renal transplant ultrasound normal.



# Debate

- 60's M DDKT 2016 c/b BK nephropathy, presenting with several weeks of falls and weakness, cough with pulmonary opacity, fever, and leg wound.

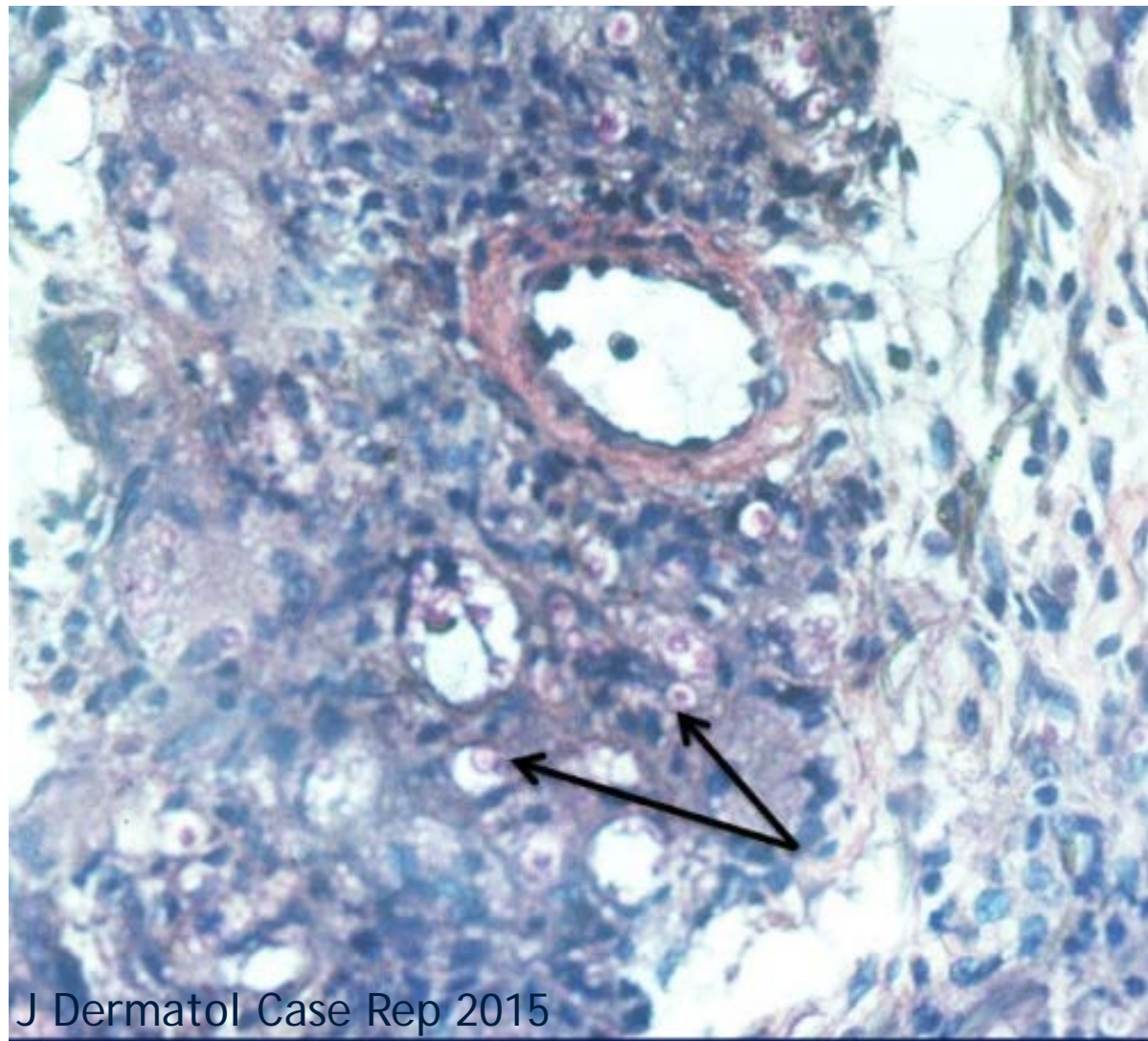
# Pathology

- Renal Bx: KIDNEY TRANSPLANT (BIOPSY): POLYOMAVIRUS NEPHROPATHY (PVN), CLASS 2



# Pathology

- Skin bx: GMS stains fungal yeasts and mucicarmine stains mucin capsule. Numerous organisms noted. Associated with ulceration, granulation and paniculitis.



J Dermatol Case Rep 2015  
3, pp 76-80



LP:

- Protein 104, glucose 20 (serum 338), 59 WBC, 5 RUB(66% L, 3% eos, 2% PMN.)
- OP 24 cmH2O

- CSF CrAg >1:320; blood Ag +. Biofire + Cryptococcus. Gram stain with few budding yeast and *C. neoformans*.

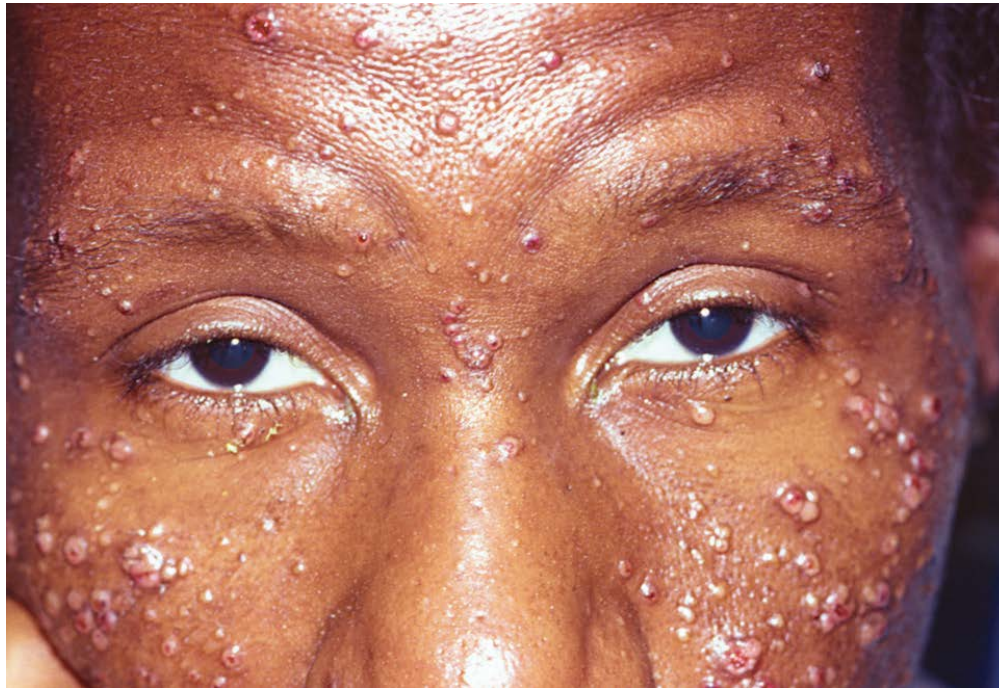# Manifestations of Cryptococcal infection

- CNS
- skin
- lung
- prostatitis
- pyelonephritis
- hepatitis
- peritonitis
- osteomyelitis

# Cutaneous lesions

- Extrapulmonary dissemination to skin in 10-15% of cases.
- Cutaneous lesions may precede other manifestations by several months.
- While primary cutaneous cryptococcus can occur, more common is disseminated disease.
- Often distributed to face and neck.
- Wide variety of lesion types.
- First present as painless papules or pustules, which then become nodules that may ulcerate (eg, pustular eruption in cardiac transplant patient with cryptococcal meningitis and headache [15] )  
Numerous other cutaneous manifestations (eg, acneiform papules or pustules, warty or vegetating crusted plaques and ulcers, hard infiltrated plaques or nodules, subcutaneous swellings, abscesses, blisters, tumorlike masses, eczematous plaques, granulomas, vasculitic lesions resembling palpable purpura [especially in transplantation patients])

# Papules, pustules

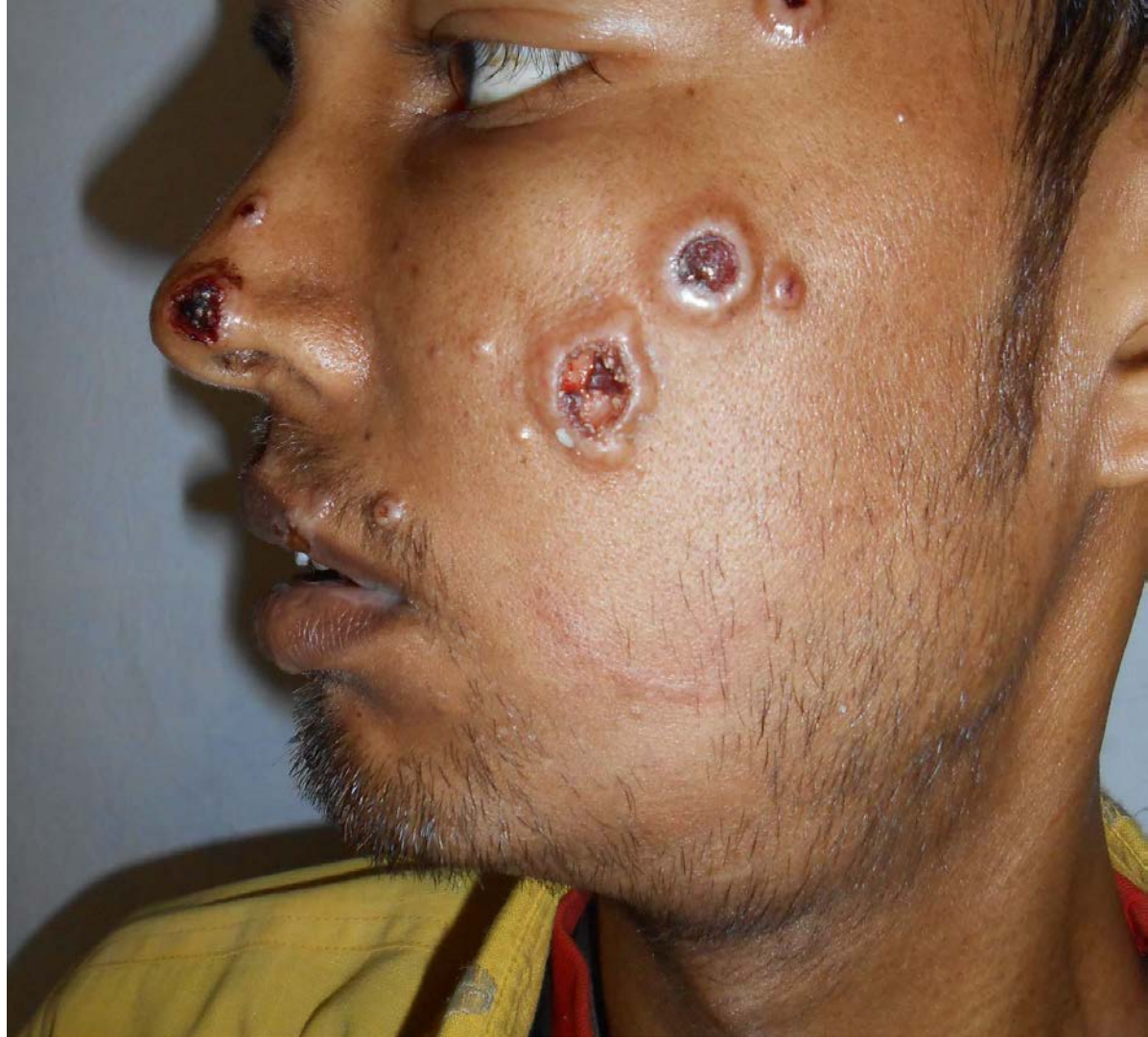

Fine HF, Chang MA, Dunn JP. Bilateral Cryptococcal Choroiditis. *Arch Ophthalmol*. 2004;122(11):1726-1727.



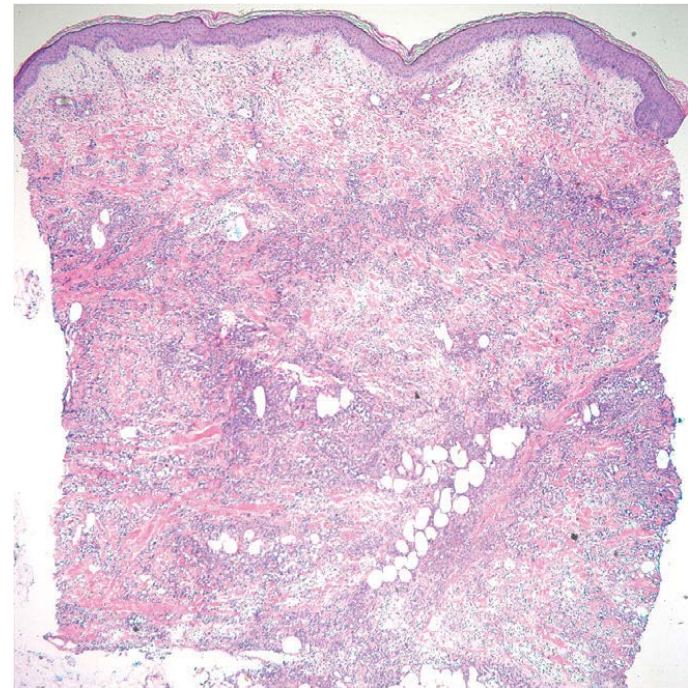
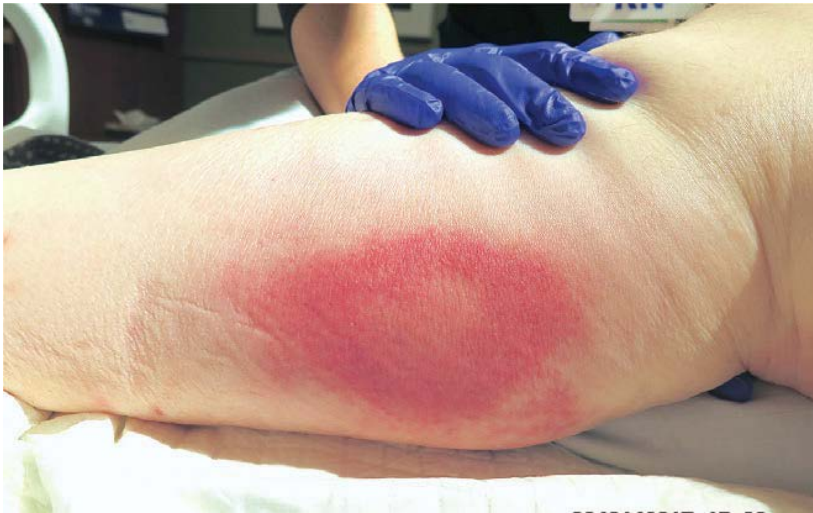Nodules,  
pustules, crust, ulcers  
with hemorrhage

- Srivastava GN, Tilak R, Yadav J, et al. BMJ-pub online 2015





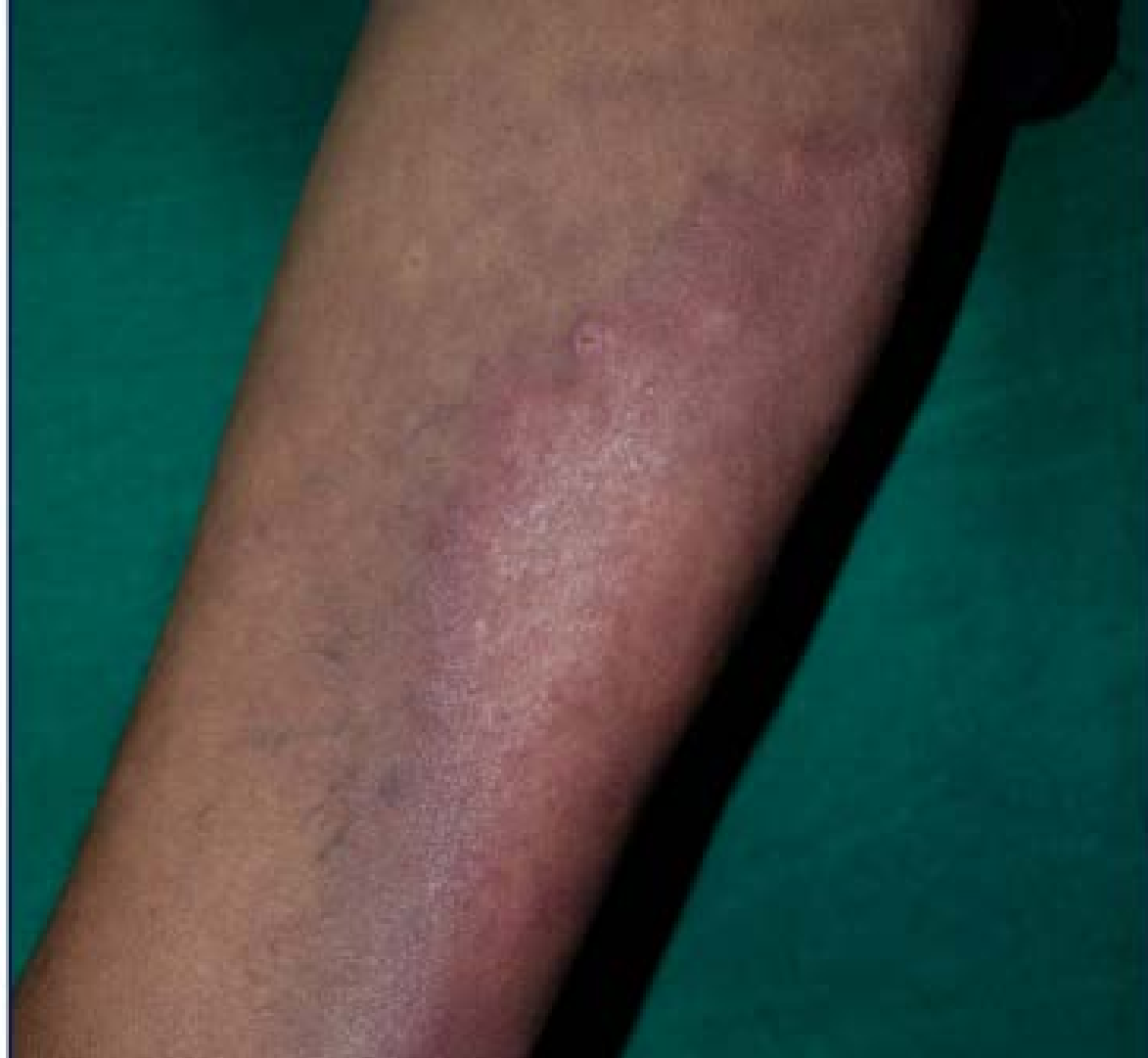# ?Cellulitis



Akbary S, Ramirez J, Fivenson D.  
Cryptococcal cellulitis: A rare entity histologically mimicking a  
neutrophilic dermatosis. J Cutan Pathol. 2018;45:90–93.

# Panniculitis

- Indurated plaque with sparing of the epidermis and poorly formed granulomas and organisms in the dermis





## Others

- First present as painless acneiform papules or pustules, which then become nodules that may ulcerate. May resemble herpetiform lesions or Basal cell cancers.
- Central necrosis/umbilication may resemble molluscum contagiosum
- warty or vegetating crusted plaques and ulcers
- hard infiltrated plaques or nodules,
- subcutaneous swellings, abscesses, blisters, tumorlike masses,
- eczematous plaques, granulomas,
- vasculitic lesions resembling palpable purpura [especially in transplantation patients])

Medscape:

Cutaneous

cryptococcosis



Jefferson

Philadelphia University +  
Thomas Jefferson University

# City Wide - Spring 2018

Noha Ghusson PGY4

TJUH Infectious Disease

# Chief Complaint



30'S YEAR OLD FEMALE WITH PMH OF MS  
PRESENTING WITH FLU LIKE ILLNESS WITH  
WORSENING NAUSEA AND VOMITING DESPITE  
TAMIFLU

# HPI

- 30's yo F with PMH of MS who was diagnosed with influenza A on 2/5 at an urgent care clinic.
- Started on Tamiflu that day and tolerating at first.
- On 2/7 patient began to have nausea and by 2/8 she was having intractable vomiting.
- Brought to the ED by friends and was found to be hypotensive, tachycardic with nausea, vomiting and complaining of severe abdominal pain.

## Additional Information

- PMH: Multiple sclerosis diagnosed in 2014
- Medications: Dimethyl fumarate, percocet, tizanidine, loestrin OCP
- Allergies: NKDA
- PSH: None
- SH: Works full time in finance. Lives in Philadelphia.
- FH: Non-contributory

# Physical Exam

- T 101.3, HR 125, BP 113/71 after IVF, SpOx 95% on 4L NC
- GEN: Severe distress, confused, diaphoretic
- EYE: PERRL, No hemorrhage, no lesions, no petechiae
- NECK: No JVD, no bruits
- PULM: Diminished breath sounds at right base
- CV: Tachycardic, no murmurs
- ABD: Severely TTP in all quadrants most notable in suprapubic region, distended, decreased BS, +rebound, +guarding
- GU: Foley with clear yellow urine. Edematous external genitalia.
- MSK: No effusions, no deformities.
- Neurologic: Opens yes to verbal stimuli, oriented to self only. Lethargic but arousable.
- Skin: Facial and neck flushing. No visible wounds or other rash.

# Additional Data



## LABS

- WBC 3.85 (16% bands, 8% lymps)
- Hgb 15.3/ Plt 138
- Cr 2.5
- Lactate 3.9
- CPK 1399 -> 1533
- HGC < 0.6
- UA: TNTC WBC, 20 RBC, 3+LE, 3+ nitrites, + bacteria
- LFTs: AST 65, ALT 20, Alk Phos 40, TB 1.8, DB 0.9

## IMAGING

- CT A/P: Large amount of retroperitoneal and extraperitoneal fluid throughout the abdomen and pelvis. Small pericardial effusion. Nonobstructing renal calculi bilaterally without hydronephrosis. Calcifications in the pelvis. Fluid filled esophagus c/w GERD. Distended gallbladder with sludge. Small bowel loops diffusely fluid filled. Decompressed colon. Bladder wall thickening.

## Hospital Course

- 2/9: Bcx sent, Ucx sent. Started on vancomycin, ceftazidime and flagyl. Tamiflu discontinued 2/2 concern for GI side effect.
- 2/10 AM: WBC peaks at 11.7 with 41% bands. ID consulted. Blood cultures drawn. Recommend transitioning to IV zosyn. Ucx +E.coli
- 2/11: OBGYN sees patient. Erythematous cellulitic appearance to skin involving labia and lower abdomen. Bimanual exam with no palpable tampon. Abdominal pain and rash worsening.
- 2/12: Patient taken to OR for laparotomy. Gross pus seen in OR. Cultures sent, gram stain with 4+ WBC, no org and NGTD.



# Discussion



SEVERE INFECTIONS PRE-DISPOSED BY FLU

# Toxic Shock Syndrome



BCX POSITIVE FOR STREP PYOGENES IN 4/4 BOTTLES. NOTED TO HAVE SIGNIFICANT ERYTHEMA OF THE EXTERNAL GENITALIA EXTENDING TO THE LOWER ABDOMINAL WALL. CLINDAMYCIN ADDED. PATIENT IMPROVED.

# Invasive Streptococcal Infections

- Streptococci sporadically causes deep seated infection resulting in shock and organ failure
- Group A streptococci (pyogenes)
- Pathogenesis:
  - GAS entry into deeper tissues and blood stream through a breach in mucous membranes (vagina, pharynx, mucosa, skin)
  - Strep A can cause deep infection of muscle and fascia without an obvious penetrating injury\*
  - Protein M prevents macrophage phagocytosis of Strep A
  - Toxin Mediated injury: Scarletina toxin, erythrot toxins, Strep exotoxins induce cytokine storm and septic shock

# Strep TSS

- Criteria:
  - Isolation of group A strep (*Strep pyogenes*) +cultures
  - Clinical signs: Hypotension & 2+ renal impairment, coagulopathy, liver involvement, ARDS, generalized erythematous macular rash that may desquamate, soft tissue necrosis (fasciitis or myositis)
- Risk factors
  - Age (infants, elderly), DM, ETOH, Surgery, Trauma, Varicella, Influenza, NSAIDs
- Presentation:
  - Initially: Fevers, chills, myalgias, n/v, diarrhea (FLU LIKE)
  - Then: Rash at entry site. If no entry site, severe pain out of proportion can be an indicator of deep invasive disease/ myositis/ peritonitis even before rash develops. Followed by shock and organ failure.
  - Elevated CK, rise in Cr, normal WBC with large left shift, imaging not helpful
- Treatment:
  - Urgent surgical debridement of infected tissues, IVF,
  - Abx: high dose penicillin + clindamycin (suppress endotoxin and M proteins)
  - IVIG (perhaps neutralize activity against strep exotoxins)
- Outcome:
  - 50% mortality

## Correlation with Influenza

- Staph aureus, Strep pneumo, H.flu post-flu PNA
- **BUT...**
- There is a notable correlation with invasive group A strep infections, rare, but severe
- CID May 2010: 10 documented cases of H1N2 influenza in 2009 with invasive GAS co-infection (worth considering)
- How influenza increases the risk of severe bacterial infection are still unknown
  - influenza may cause viral immunosuppression
  - alteration in cytokine production
- Lesson: Still check Bcx if sick enough, despite +flu



**Jefferson**

Philadelphia University +  
Thomas Jefferson University

---

HOME OF SIDNEY KIMMEL MEDICAL COLLEGE