Cause of Death Due to Complications of Lipomatous Hypertrophy of the Interatrial Septum

DREXEL UNIVERSITY
Graduate School of
Biomedical Sciences
and Professional Studies
College of Medicine

Sarah Lock, Khalil Wardak, MD

Drexel University Graduate School of Biomedical Sciences and Professional Studies, Montgomery County Coroner's Office

MONTGOMERY COUNTY, PA
OFFICE OF THE CORONER

Abstract

Lipomatous hypertrophy of the interatrial septum (LHIS) is a benign condition characterized by the accumulation of adipose tissue in the interatrial septum, which spares the fossa ovalis. While LHIS is not a true tumor, it should be considered in the differential diagnosis when an adipose cardiac tumor, such as a cardiac lipoma, is discovered. Most cardiac tumors are benign, and many are incidentally diagnosed upon autopsy. However, due to the location and size, benign cardiac tumors may impede blood flow and cause arrhythmias, leading to death. We report the case of a woman who died due to complications of previously-undiscovered LHIS.

Background

Cardiac tumors are a very rare occurrence, evidenced by autopsy studies revealing a cardiac tumor prevalence of 0.02%.[1] While cardiac tumors can be accompanied by a range of symptoms depending on tumor size, exact location in the heart, and amount of invasion into neighboring tissue, they may also be clinically silent. As a result, many of these tumors remain undetected throughout a person's life, only to be revealed upon autopsy. Approximately 75% of these tumors are benign, with lipomas comprising 14% of benign cardiac tumors.[2,3]

Cardiac lipomas are encapsulated growths of adipose tissue comprised of homogenous, mature adipocytes with intervening fine fibrous trabeculae and minimal to no cellular atypia.[4] They are most often found in the subendocardial region, usually in the right atrium, left ventricle, or atrial septum.[5] They can occur in any age group, but are most prevalent in people between 40–60 years of age.[5] There is no difference in the distribution between men and women, and the exact etiology is unknown.[6] While many cardiac lipomas remain asymptomatic, they can also cause obstruction of intracardiac blood flow, cardiac valve dysfunction, obstruction of the the venae cavae, and phrenic nerve involvement.[7] As a result, patients may experience sudden death from severe arrythmia or acute coronary occlusion due to the lipoma's position in the heart.[6]

When an adipose cardiac tumor is discovered, lipomatous hypertrophy of the interatrial septum (LHIS) should be considered within the differential diagnosis. While LHIS is a rare pathology, it occurs more commonly than cardiac lipoma.[8] LHIS is a benign anomaly characterized by a >2.0 cm thick, non-encapsulated collection of adipose tissue comprised of mature adipocytes (and occasional fetal adipose tissue) with interspersed strands of non-lipomatous cells (usually cardiomyocytes).[5] Unlike its name suggests, LHIS is not a type of lipoma (due to the lack of a capsule), and the adipocytes of LHIS are characterized by hyperplasia instead of hypertrophy.[9] The condition is associated with obesity, older age, female sex, coronary artery disease, and steroid use.[10,11] Like cardiac lipomas, LHIS can be asymptomatic and discovered only incidentally upon imaging or autopsy. LHIS can cause symptoms such as arrhythmias, atrioventricular block, and venous return obstruction, resulting in sudden death in rare instances.[10,12] Echocardiography can detect LHIS, which characteristically appears as a pathognomonic dumbbell-shaped mass of the interatrial septum which spares the fossa ovalis.[11]

Figure 1: Example of cardiac lipoma.[13]

Figure 2: Example of LHIS.[14]

Case Report

A 76-year-old overweight, white female was found unresponsive in her home. At the time she was found, she did not have a pulse and her face was described as blue-purple. Emergency medical services personnel pronounced the female deceased at the scene. There was no evidence of trauma, abuse, neglect, drug use, or foul play, and the decedent had no history of suicidal ideations.

Empty liquor bottles were found at the scene, but it is unknown if the alcohol was consumed by the decedent on the date of her death. She had a prior medical history of hypertension and chronic alcoholism. Her only known prescription medication was Plavix.

Autopsy and Toxicology Findings

A forensic autopsy was performed on the decedent, with internal examination limited to the heart and lungs. The external examination revealed no evidence of injury or medical intervention.

Cardiovascular

The pericardial surfaces are smooth, glistening, and unremarkable. The pericardial sac is free of significant fluid or adhesions. The coronary arteries followed the usual distribution and are diffusely calcified, with minimal atherosclerotic stenosis. No thrombosis is identified. All heart chambers and valves exhibit the usual positional relationships. All valve leaflets are thin and pliable. The myocardium is red-brown and firm with no focal lesions. The ventricular septum is intact. The aorta and its major branches are patent, arise normally, and follow their usual course. The vena cavae and their major tributaries return to the heart in the usual distribution and are free of thrombi. Both ventricles are dilated and the heart is markedly enlarged.

Entrapped within the interatrial septum, there is a 5.0 x 1.5 x 1.5 cm firm mass that encroaches into the right and left atria (Figure 3). This mass is immediately adjacent to the fossa ovalis, but does not involve it.

Table 1: Cardiac measurements taken during autopsy

Part of Heart	Measurement for Decedent
Right ventricle (space)	5.0 x 5.0 cm
Right ventricle thickness	0.6 cm
Left ventricle (space)	4.5 x 4.0 cm
Left ventricle thickness	1.4 cm
Interventricular septum thickness	1.4 cm
Tricuspid valve	13.0 cm
Pulmonary valve	7.0 cm
Mitral valve	11.0 cm
Aortic valve	8.0 cm
Heart weight	490.0 gm

Respiratory

The right lung weighs 490.0 gm and the left lung weighs 390.0 gm. The upper airway is free of debris and foreign material. The mucosal surfaces are smooth, tan-yellow, and unremarkable. The pleural surfaces are irregular with adhesions. The pulmonary parenchyma is red-purple with minimal to moderate amounts of frothy fluid. No lesions are identified. The pulmonary arteries are normally developed and patent without thrombi or emboli.

Table 2: Toxicology results from decedent

Substance	Value for Decedent
Ethanol	31 mg/dL
Blood alcohol concentration	0.031 g/100 mL
Caffeine	Positive mcg/mL
Acetaminophen	13 mcg/mL
Trazodone	0.097 mcg/mL

Gross Findings

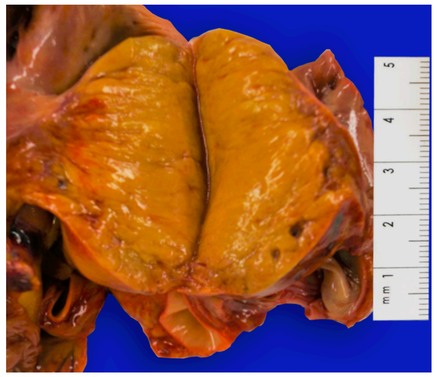

Figure 3: Cut surfaces of the interatrial septum mass

Sectioning through the 5.0 x 1.5 x 1.5 cm, firm interatrial septum mass revealed tan-yellow, glistening, smooth, homogenous, adipose cut surfaces. The mass was un-encapsulated and well-circumscribed in relation to the interatrial septum myocardium.

Microscopic Findings

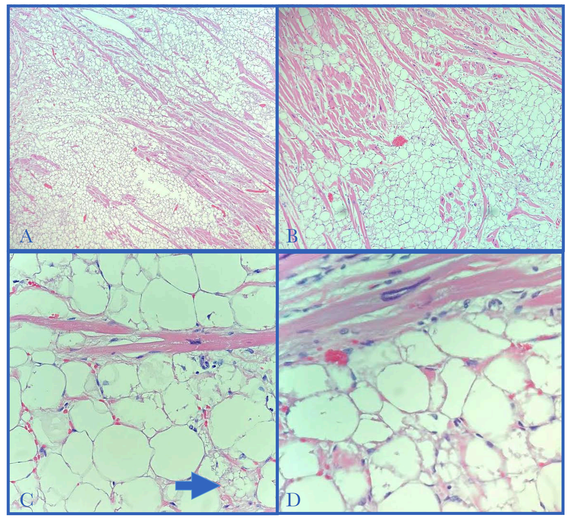

Figure 4: H&E images of the interatrial septum mass. **A:** 40X image of adipose tissue interspersed with myocardial tissue. **B:** 100X image showing adipose tissue interspersed with myocardial tissue. **C-D:** 400X images of adipocytes with adjacent cardiomyocytes. The blue arrow indicates a multilocular adipocyte.

Histologic examination of the mass reveals hyperplastic, infiltrative growth of adipose tissue within the interatrial myocardial tissue. The adipose tissue is un-encapsulated, and islands of cardiomyocytes are interspersed between the adipocytes. The adipose tissue is composed almost entirely of non-neoplastic, mature, unilocular adipocytes. There are occasional fetal fat-type multilocular adipocytes, one of which is highlighted by the blue arrow (Figure 4).

Discussion of Findings

The forensic autopsy revealed several findings, the most significant of which was the enlarged collection of adipose tissue within the interatrial septum. This condition was determined to be LHIS, and was able to be grossly and microscopically distinguished from a cardiac lipoma. The mass occurred within the atrial septum, which is supporting evidence for LHIS. The mass was grossly un-encapsulated, whereas cardiac lipomas are characterized by the presence of a collagenous capsule. Microscopically, the hyperplastic adipose tissue infiltrated the cardiomyocytes with no capsule to keep it separated from the myocardial tissue. The adipocytes were primarily unilocular with occasional multilocular, fetal fat-type adipocytes, which is characteristic of LHIS.

The decedent's coronary arteries were diffusely calcified with minimal atherosclerosis. The heart exhibited cardiomegaly and both ventricles were dilated, which is an established finding in chronic alcoholics. The respiratory and toxicology findings were considered unremarkable.

Although LHIS is not a true tumor, it should be considered in the differential diagnosis when a cardiac mass is discovered. LHIS was first described in 1964 during an autopsy, and has a prevalence ranging from 2.2-8% in living patients, depending on the modality of detection.[15] The exact etiology is unknown, however, it has been proposed that fat accumulation occurs during embryological development of the interatrial septum; During fusion of the region of the fossa ovalis with the primitive atrial wall infoldings, mesenchymal cells can become trapped within the atrial wall and can later develop into mature adipocytes with certain stimuli.[16] LHIS has been associated with arrhythmias that can cause sudden death; One possible explanation for this is the progressive disruption of cardiomyocytes due to fat accumulation, disorganizing the fibers and disrupting proper atrial depolarization, leading to fibrosis and resulting in impaired contractility and electrical conduction.[16] Differential diagnoses for LHIS mainly include lipomas and myxomas, as well as metastases, rhabdomyomas, lymphomas, and mesotheliomas.[16]

Based on the autopsy findings, the decedent's cause of death was listed as "complications of lipomatous tumor of cardiac septum." Gross and microscopic evidence supports the diagnosis of LHIS.

References

1. Hoffmeier A, Sindermann JR, Scheld HH, Martens S. Cardiac tumors--diagnosis and surgical treatment. *Dtsch Arztebl Int*. 2014;111(12):205-211. doi:10.3238/arztebl.2014.0205
2. Ismail I, Al-Khafaji K, Mutyala M, et al. Cardiac lipoma. *J Community Hosp Intern Med Perspect*. 2015;5(5):28449. Published 2015 Oct 19. doi:10.3402/jchimp.v5.28449
3. Bath AS, Gupta V, Kalavakunta JK. A right atrial fat ball: Rare case of cardiac lipoma. *Clin Case Rep*. 2019;7: 179801799. https ://doi.org/10.1002/ccr3.2335
4. Rocha RV, Butany J, Cusimano RJ.Adipose tumors of the heart. *J Card Surg*. 2018;33:432–437.https://doi.org/10.1111/jocs.13763
5. D'Souza J, Shah R, Abbass A, Burt JR, Goud A, Dahagam C. Invasive Cardiac Lipoma: a case report and review of literature. *BMC Cardiovasc Disord*. 2017;17(1):28. Published 2017 Jan 14. doi:10.1186/s12872-016-0465-2
6. Shu, S., Wang, J. & Zheng, C. From pathogenesis to treatment, a systemic review of cardiac lipoma. *J Cardiothorac Surg* 16, 1 (2021). https://doi.org/10.1186/s13019-020-01379-6
7. Fahad Syed Naseerullah, Hemangkumar Javaiya, Avinash Murthy, "Cardiac Lipoma: An Uncharacteristically Large Intra-Atrial Mass Causing Symptoms", *Case Reports in Cardiology*, vol. 2018, Article ID 3531982, 3 pages, 2018. https://doi.org/10.1155/2018/3531982
8. Singh S, Singh M, Kovacs D, Benatar D, Khosla S, Singh H. A rare case of a intracardiac lipoma. *Int J Surg Case Rep*. 2015;9:105-108. doi:10.1016/j.ijscr.2015.02.024
9. Silbiger J, Bazaz R, Trost B. Lipomatous Hypertrophy of the Interatrial Septum Revisited. *Journal of the American Society of Echocardiography*. 2010;23(7):789-790. doi:https://doi.org/10.1016/j.echo.2010.04.015
10. Pugliatti P, Patanè S, De Gregorio C, Recupero A, Carerj S, Coglitore S. Lipomatous hypertrophy of the interatrial septum. Int J Cardiol. 2008 Nov 12;130(2):294-5. doi: 10.1016/j.ijcard.2007.07.012. Epub 2007 Aug 21. PMID: 17714811.
11. Hejna P, Janík M. Lipomatous hypertrophy of the interatrial septum: A possibly neglected cause of sudden cardiac death. *Forensic Science, Medicine, and Pathology*. 2013;10(1):119-121. doi:10.1007/s12024-013-9480-0
12. Laco J, Steiner L, Tomsová M. Lipomatózní hypertrofie mezisinového srdečního septa [Lipomatous hypertrophy of the cardiac interatrial septum]. Cesk Patol. 2006 Oct;42(4):182-5. Czech. PMID: 17171973.
13. Mankad R, Herrmann J. Cardiac tumors: Echo assessment. Echo Research and Practice. https://erp.bioscientifica.com/view/journals/echo/3/4/R65.xml. Published December 1, 2016.
14. Lipomatous Hypertrophy of the Atrial Septum. Brown Biology and Medicine. https://www.brown.edu/academics/biomed/departments/pathology/residency/digital-pathology-library/cardiovascular/lipomatous%C2%A0hypertrophy-atrial-septum. Published 2022.
15. Xanthopoulos A, Giamouzis G, Alexopoulos N, Kitai T, Triposkiadis F, Skoularigis J. Lipomatous hypertrophy of the interatrial septum: A case report and review of the literature. *CASE*. 2017;1(5):182-189. doi:10.1016/j.case.2017.06.005
16. Laura DM, Dominno R, Kim EE, Benenstein R, Freedberg RS, Saric M. Lipomatous atrial septal hypertrophy: A review of its anatomy, pathophysiology, multimodality imaging, and relevance to percutaneous interventions. *Journal of the American Society of Echocardiography*. 2016;29(8):717-723. doi:10.1016/j.echo.2016.04.014